

ATYPICAL YAWS¹

PAUL W. WILSON

From the Gorgas Memorial Laboratory, Panama, R. de P.

This study is based on a series of 424 consecutive cases of yaws seen in the province of Darien, Panama, from July, 1932, to August, 1933. For purposes of comparison some of the findings are tabulated beside those found in a similar series of 1423 cases reported from Haiti in 1930 (1).

When this work was undertaken it was felt that some of the points brought out by the Haitien work merited further investigation. Schöbl and his associates, from their excellent work in Manila on experimental yaws in monkeys extending over a period of more than twelve years, have made several interesting observations, namely: First, that all of the secondary lesions in monkeys occur as a result of scratching, the infectious material being thus transferred over the surface of the body from the primary lesion. Second, that, besides the skin, only the regional lymphatic glands are invaded by the *T. pertenue*, and that the organism is not transferred in monkeys to other parts of the skin surface through the lymphatic system or by the general circulation. Third, that in those monkeys which developed a widespread and destructive lesion of the small bones and soft tissues within the nose and nasopharynx, simulating gangosa in man, the process was always a direct extension from a skin lesion of the face and nares on to the nasal mucous membrane (2).

In the course of this work an attempt was made to report carefully on the adenopathy found in each case. Early in the work it was found that there were but relatively few constant adenopathy findings that could be considered of any value whatever. Many and frequent previous skin infections had so distorted the

¹ Read at the twenty-ninth annual meeting of the American Society of Tropical Medicine, Richmond, Va., November 15, 16 and 17, 1933.

adenopathy picture that it was often impossible to tell just how much could be attributed to yaws, even in a florid secondary eruption. In fact several cases of widespread general secondary eruption showed no general adenopathy. Certainly yaws seems to cause a regional adenitis, particularly in those glands draining the region of the primary lesion, or "mother yaw," but even here it is impossible to say how much should be attributed to *T. pertenue* and how much to the usual accompanying mixed infection. One observation should be noted, however, and that is, the relative doughy consistency of yaws adenopathy as compared with the hard, shotty adenitis of syphilis. This has also been noted by Schöbl in his work on animals.

There are presented here 20 cases which have been chosen to illustrate various atypical courses that yaws may follow, and which, it is believed, will bring out some illuminating details in the field of the pathogeny of the disease.

Case 1. (Fig. 1.) Boy seven years old, mother yaw on the left ankle one year earlier. No secondaries until the present solitary yaw on the left knee, first noticed two weeks before this picture was taken. The left popliteal gland was markedly enlarged; left inguinal gland slightly enlarged. No other adenopathy was noted. Here the question of reinfection arises. In all probability this is not a reinfection since secondaries often do not appear until six or eight months after the primary sore and may even fail to appear at all. Furthermore, the appearance of this lesion is not that of a mother yaw but that of a typical secondary. The mother yaw is usually more spread out, irregular in outline and deeper in the skin, due to the fact which has been pretty well established that the mother yaw starts *in* the skin through a previously existing scratch or abrasion, while the typical secondary is *on* the skin and usually regularly circular or serpiginous in form. The mother yaw usually leaves a scar which persists while the secondary never leaves a persistent scar unless there is mixed infection with ulceration. It is also considered that one year is too early for reinfection to take place. The yaw seen here disappeared without scar formation after two doses of 0.2 gram neosalvarsan.

Case 2. (Fig. 2.) Boy of eight years, with a persistent mother yaw on the plantar surface of the left fourth toe. Many actively motile

T. pertenue were found by darkfield examination in serum taken from this lesion. Lesion has been present for one year. There has been no secondary lesion and adenitis is more marked in the left groin. Lesion healed completely after two doses of 0.2 gram neosalvarsan.

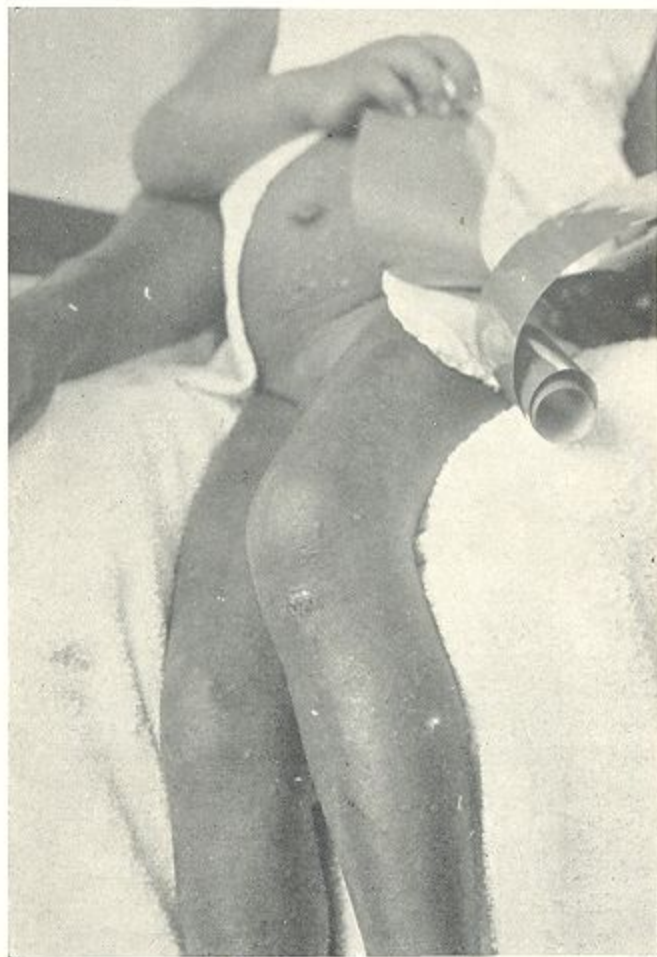


FIG. 1. CASE I

Case 3. (Fig. 3.) Indian woman twenty years old. Eighteen months earlier had mother yaw middle third of the right leg. The ulcer here seen is at the site of the mother yaw. She has had no secondary

eruption. There is a non-tender definite right inguinal adenopathy. No adenopathy noted elsewhere. Kahn and Wassermann reactions both 4 plus. Her daughter, three years old, has a small mother yaw on the ring finger of the right hand, present for three months and positive for *T. pertenue*. This lesion healed promptly following local applications of carbarsone, but another yaw was seen on a finger of the left hand about three weeks later. This also reacted quickly to the same local treatment. No adenopathy has been observed. When seen last, two months after the second finger lesion had been treated, no other secondaries

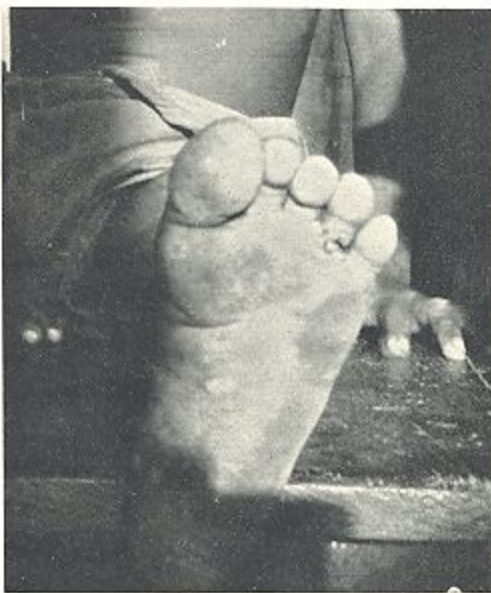

FIG. 2. CASE 2

were found. It is of course too early to give any prognosis for the child's yaws, but this would appear to be another case of an attenuated strain of *T. pertenue* infecting two members of the same family. It should be added that, generally speaking, the Darien Indians so far observed do not have the extensive skin lesions of yaws observed among the other inhabitants. Perhaps this may be due to different personal customs and habits. Every indian bathes several times a day and most of the body is uncovered except at night.

Case 4. (Fig. 4.) Boy of eleven years, with an ulcer of the left shin on the site and two years after the appearance of the mother yaw.

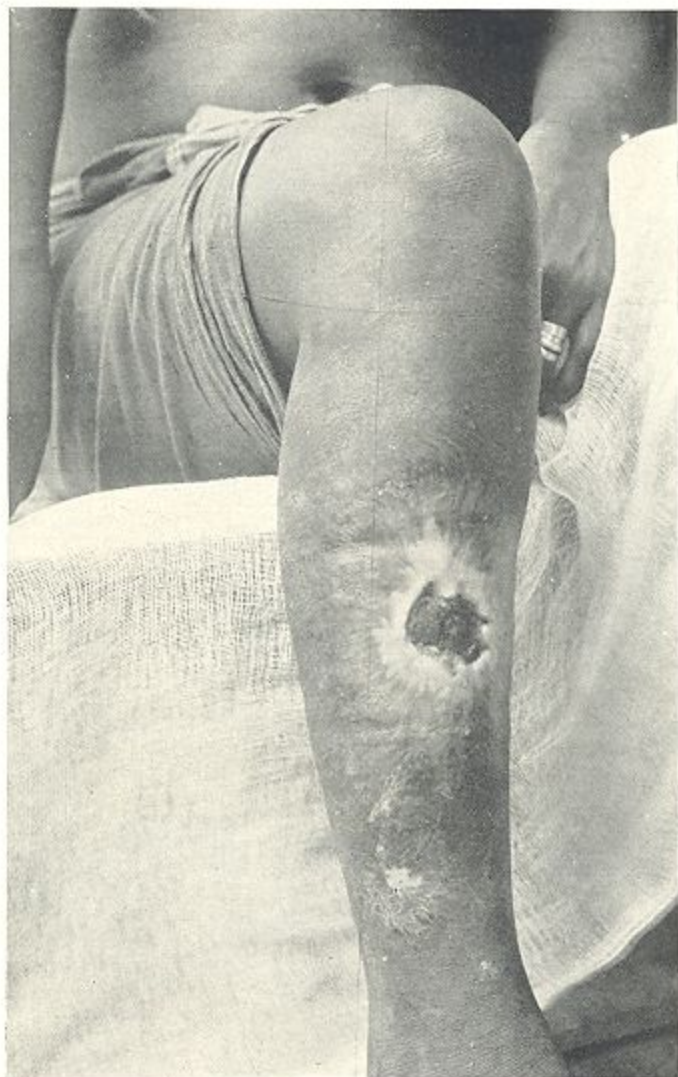

FIG. 3. CASE 3

Slight periostitis present extending outward from beneath the ulcer. In this connection it should be mentioned that all the bone lesions seen

in Panama with but two other exceptions, cited later, were direct extensions from an overlying yaws ulcer. This is in contrast to what was

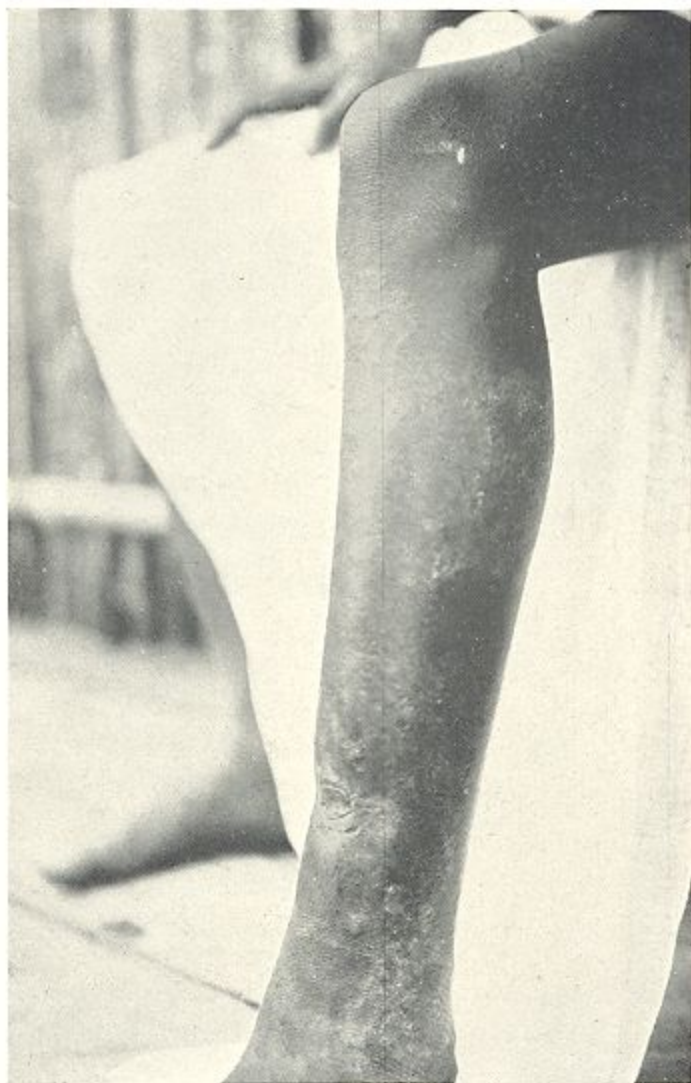

FIG. 4. CASE 4

found in Haiti where not infrequently bone involvement was observed without old scars or ulcers of the skin overlying the bones involved;

sabre shins were the most usual manifestations but many other bones were also affected. This case also showed marked left inguinal adenitis which was not tender, but it is hardly significant of yaws infection in view of the long standing ulceration and mixed infection that always

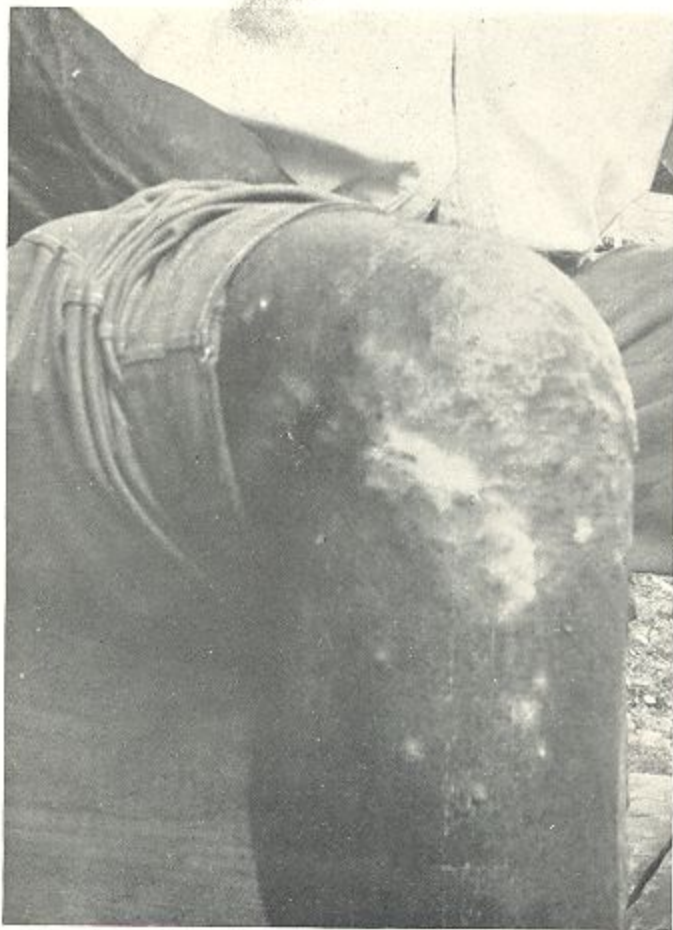

FIG. 5. CASE 5

occurs in such cases. The ringworm-like, furfuraceous eruption of the skin of the leg is also of interest in that it did not react to the usual treatment for ringworm but did react favorably to neosalvarsan. The adenitis also reacted well to specific treatment but this might have been due

to the healing of the ulcer. This boy has never had any other secondary yaws lesions. Both Wassermann and Kahn were 4 plus.

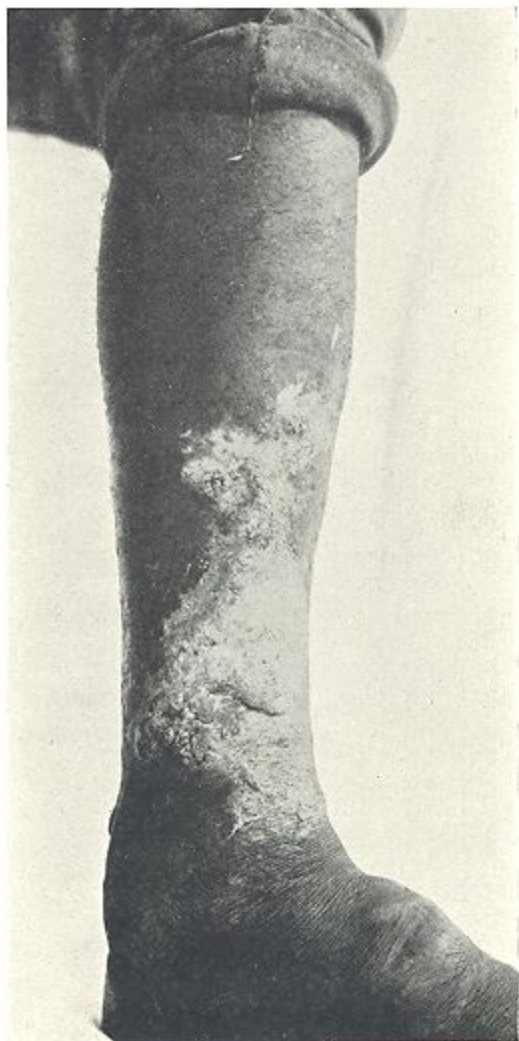

FIG. 6. CASE 6

Case 5. (Fig. 5.) Man forty-two years old, who had his mother yaw on the outer surface of the right knee six years earlier. During the past two years he has had a spreading lesion of the skin now covering the

knee and extending outward from the scar of the mother yaw. The lesion resembles a "tubercular syphiloderm." He has never had any other secondary eruption. Three doses of 0.45 gram neosalvarsan were sufficient to cause almost complete disappearance of this lesion.

Case 6. (Fig. 6.) Man twenty-four years old who states that he has never had yaws. This lesion began about four months previous to the picture as a small, raised, yellowish, weeping nodule in the skin of the right leg which has slowly spread as a markedly thickened, condyloma-like growth exuding considerable foul-smelling, blood tinged serum.

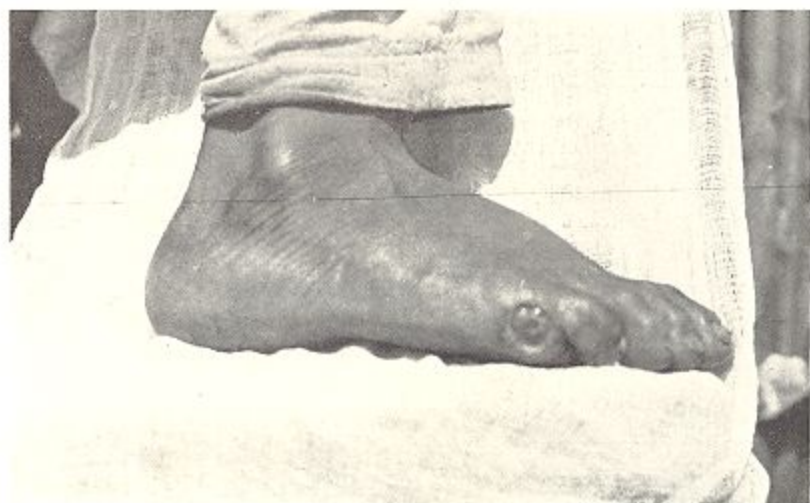

FIG. 7. CASE 7

Darkfield examination only revealed large numbers of large, actively motile and loosely coiled spirochetes, probably *T. refringens* or *T. noguchii*. This type of mixed infection is not infrequently encountered in both Panamanian and Haitien cases. There was marked right inguinal adenitis which was not tender. Blood Kahn and Wassermann both 4 plus. No secondaries have been noted. Improved rapidly under specific treatment.

Case 7. (Fig. 7.) Boy fifteen years old, with primary lesion on the outer border of the right foot which was first noticed three months previously as a more typical yaw. None of the lymph glands are palpably

enlarged. At present the lesion is ulcerated and painful under the callous surrounding the ulcer. Darkfield examination revealed many actively motile *T. pertenuis* with a larger and more loosely coiled spirochete which was not identified. Only local treatment was applied to the lesion which consisted of a daily scrubbing with soap and water and application of carbarson powder to the lesion. Lesion healed in ten days and when last seen six months later there was no recurrence and there had been no secondary lesions. Kahn and Wassermann tests both negative on two occasions. In connection with this case it is interesting to know that this boy's brother gives a history of mother yaw on the left shin two years earlier. He has had no secondaries; received no specific treatment and now has no palpable adenopathy. On one occasion the brother's blood tested Kahn 3 plus, and when checked again 2 plus but serum sent to the Public Health Laboratory, Ancon, was negative to both Kahn and Wassermann in both instances. It has been occasionally noted that there seems to be a marked similarity in reaction to yaws infection among different members of the same family due, probably to higher familiar resistance or (what is more likely) to an attenuated strain of the organism infecting that particular group. Resistance to arsenical therapeutic action has been observed among several members of the same family in several instances in both Panama and Haiti.

Case 3. (Fig. 8.) Boy of fourteen, first seen about three weeks before this picture was taken when he had what appeared to be a large abscess of the left wrist. The tumor was not very tender and there was but little surrounding inflammatory edema. Tumor had been present for three months and slowly growing larger. The gumma-like mass was opened and found to be filled with a large amount of granulomatous material, some necrotic material and bloody serum. There was no involvement of the bone. At this time the boy denied yaws. Kahn and Wassermann tests were found to be 4 plus and his mother then furnished the information that he had had yaws when a baby of two years but "that only a few yaws came out." At that time he received no specific treatment. The lesion shown was treated with carbarson powder locally, later 5 per cent carbarson in lanolin and iodoform in ether. Carbarson was ministered internally in the usual dosage. Progress was slow. Later he was given stovarsol alternating with potassium iodide and healing was much more rapid. The left epitrochlear gland in this case was rather large,—the size of a small olive, but not tender. In

attempting to needle the gland for a specimen for darkfield the needle broke and the gland was excised. Serum from cut surface of the gland was negative for treponemata, and up to date no treponemata have been found in the silver or Giemsa stained sections. Five months after the wrist lesion had healed he came to the clinic for crab yaw of the foot.

Case 9. (Fig. 9.) Man nineteen years old, history of yaws at the age of three. Now has crab yaws of both feet and widespread, circinate, ringworm-like lesions on legs, shoulders and abdomen. Stained smears and darkfield examinations of serum taken from the denuded surface

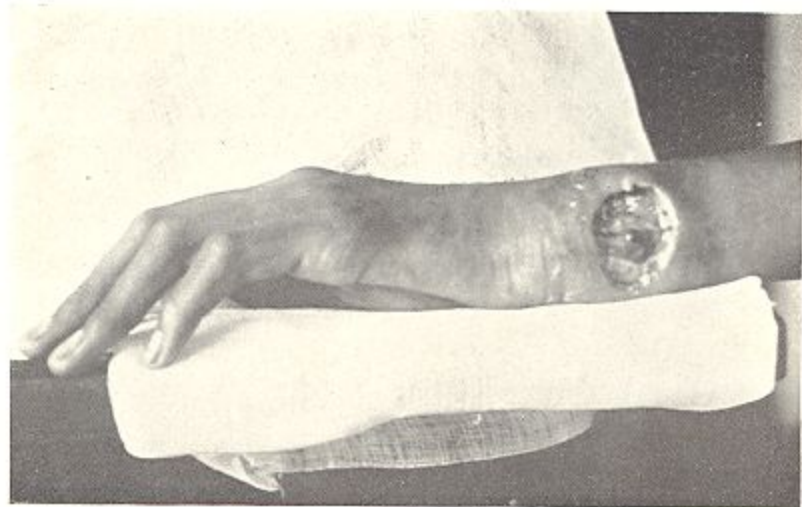

FIG. 8. CASE 8

of the advancing edge of the lesions were negative for treponemata. After two doses of 0.45 gram neosalvarsan he showed marked improvement. The so-called "tertiary" lesions of this type are not uncommon in late yaws, but in several Panamanian cases this same type of lesion has been seen very early in the disease and actually replacing the usual granulomatous secondary eruption.

Case 10. (Fig. 10.) Girl of thirteen months, with "buba seca" or "dry yaws" around the ankles, knees and elbows. "Buba seca" is the term applied to such lesions by the natives and is fairly descriptive. It is a small papule that does not increase in diameter beyond a quarter of

an inch. When the superficial epithelial layer was peeled off there was found a smoothly rounded, slightly elevated and glistening base, and

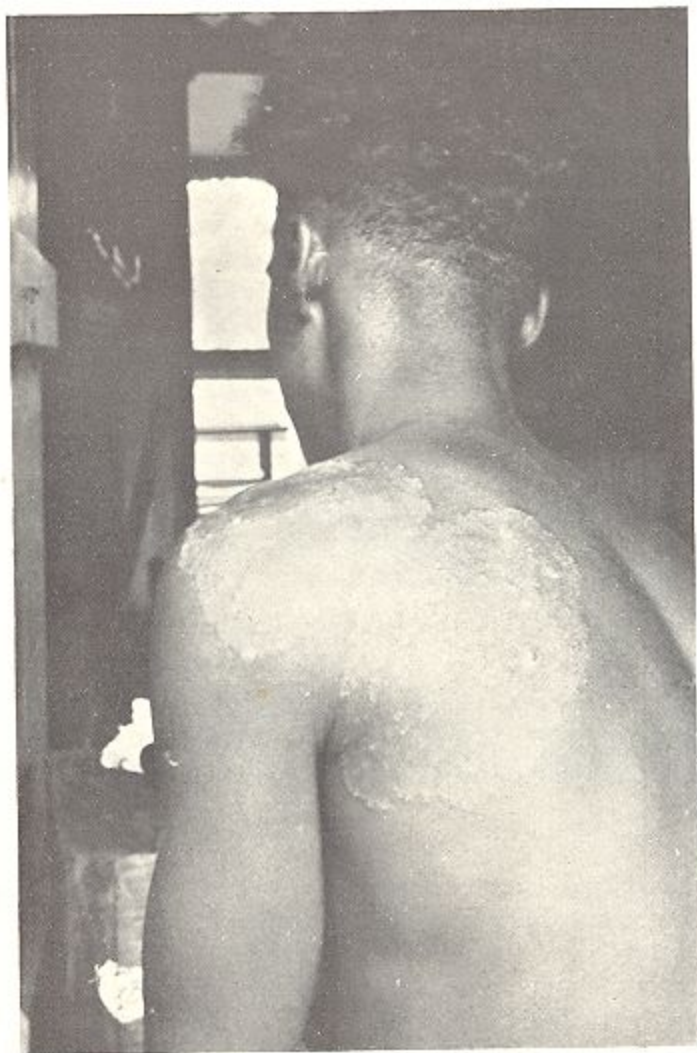


FIG. 9. CASE 9

the minute amount of serum obtained after friction contained a few actively motile *T. pertenuis*. In the very early days of the secondary lesions there is a similar papular stage, but then the papule grows

fairly rapidly, soon the serum becomes yellowish in color and can be distinguished through the thin, stretched epithelial covering and usually

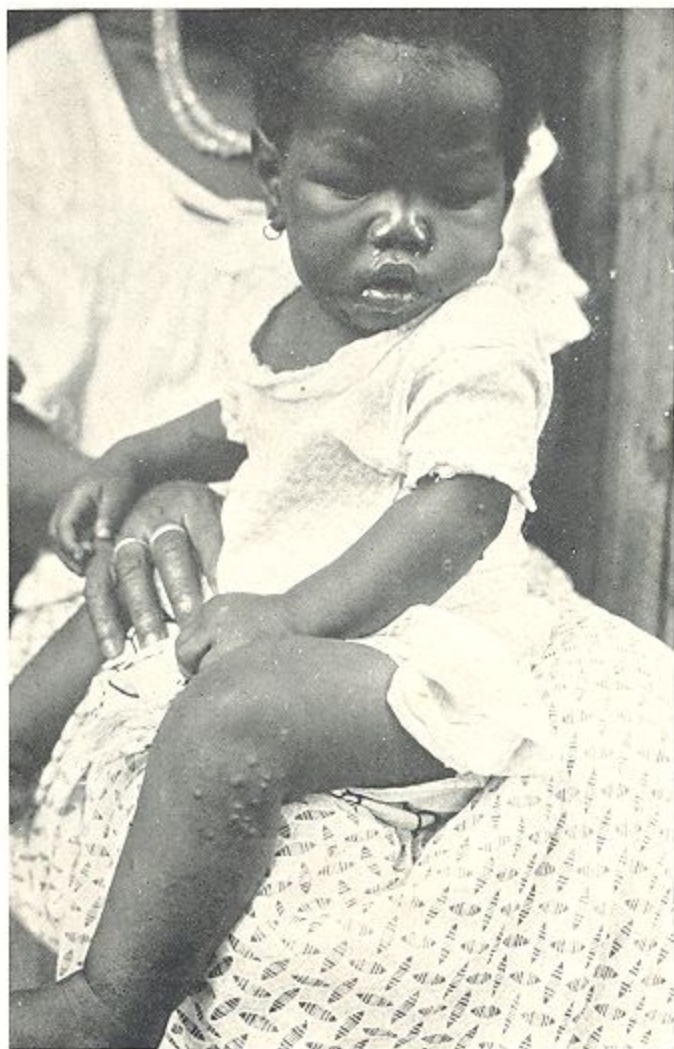

FIG. 10. CASE 10

within ten days or two weeks the usual secondary yaw has attained its typical raspberry appearance. "Dry yaws" of this type are occasionally seen in the terminal weeks of a healing secondary eruption which is al-

most completely healed without having received specific treatment. It is also occasionally encountered where insufficient specific treatment has been given, the mother bringing the child for more treatment when she sees the dry yaws appearing after the original crop of secondaries have appeared. This is the only case of *early* secondaries observed where the eruption had remained stationary in this early papular phase for such a long period—one month. This child also had a large, typical "wet yaw" of the vulva, present for a like period. This type of lesion,

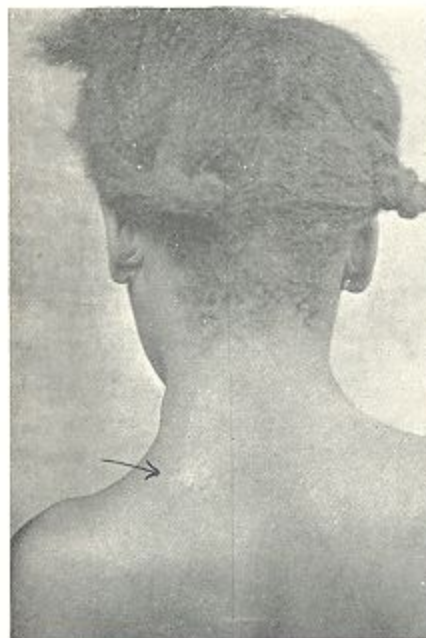

FIG. 11. CASE 11



FIG. 12. CASE 11

coming on in the last days of a healing secondary eruption, has been observed to persist for many months or as long as the cases could be observed, and not infrequently patients have given a history of "dry yaws" persisting for more than a year. Some of the papules are as small as a pin head and, of course, there must be others smaller still which cannot be seen. Usually they give rise to no itching or other subjective symptoms. They probably explain where the *T. pertenuis* remain relatively latent in the skin for long periods of time—even many years. In this particular case, located as the lesions are—around the joints—the ques-

tions presents itself that, is it not probable that these lesions account for the juxta articular nodes of late yaws?

Case 11. (Figs. 11 and 12.) Girl of eleven years—mother yaw on the left shoulder. This type of lesion is also called a “dry yaw” by the natives, but it is quite different from the dry, abortive, papular type cited above. This is a ringworm-like infection; the lesions are roughly circular or oval in form with slightly raised nodular edges and some furfuraceous scaling of the central portion. The adenopathy of the glands draining the mother yaw was rather marked in this case. The mother yaw was first seen eight months earlier, and it has persisted in about the same size and shape since about two weeks after it was first noticed. The first secondary lesion was seen about six months earlier on the left foot and two months later similar lesions were noticed on the right shin, left leg, left ring finger and just above the left knee. Adenopathy was also noted of both inguinals and left epitrochlear but not nearly as marked as that seen in the group of glands draining the mother yaw in the left supra scapular region. The adenitis is of significance in this case, as there was no ulceration or any oozing of serum from any of the lesions—no gross appearance of mixed infection. Wassermann and Kahn both 4 plus. This type of mother yaw is extremely rare. After one dose of 0.3 gram neosalvarsan all lesions disappeared within two weeks and when seen three months later only the mother yaw had left a small depigmented scar.

Case 12. (Fig. 13.) Girl two years old who was vaccinated six months previously with what was thought to be a good “take” but the lesion did not heal. When first seen a week before this picture was taken there was present a typical fungating mother yaw teeming with actively motile *T. pertenuis*. Carbarsone ointment has been applied daily and now only the rapidly healed lesion is seen. Left axillary adenitis was marked and two weeks later the usual secondary lesions appeared on the face and limbs. This child has proved to be fairly resistant to intravenous arsenical therapy.

Case 13. (Figs. 14 and 15.) Woman thirty-two years old and the mother of the child just cited as case 12. During the early days of the child's secondary eruption the mother noticed a small patch of eczema-like eruption on the back of the left forearm just above the wrist which has slowly spread to the size of a dollar. Four to six days later the le-

sions of the forearm were noticed by the patient. All of these lesions were under the skin and a few of them appeared to be coming up to the surface of the epidermis. On the mesial surface of the arm and forearm

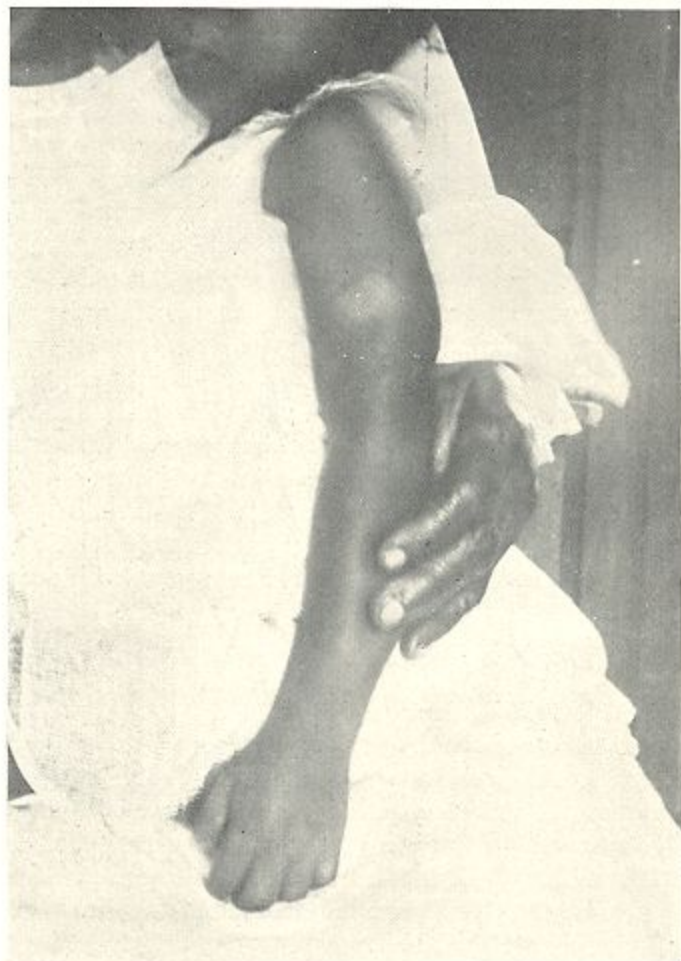


FIG. 13. CASE 12

the same lesions were noted. On palpation long chains of nodules could be felt deeper in the tissues; nodules varying in size from that of a buck-shot to a hazel nut. The epitrochlear gland (left) was usually large, about the size of a large olive, and not tender. The patient complained

of no pain or itching and had no other symptoms. Several lesions near the surface were scarified and the serum obtained was examined by darkfield for treponema. Repeated and prolonged search revealed nothing of interest. The Wassermann reaction was 1 plus and the Kahn 4 plus on blood taken three weeks after the initial lesion was first noticed. This is the only case of its kind that has ever been observed by the writer. Its resemblance to sporotrichosis is marked. It is

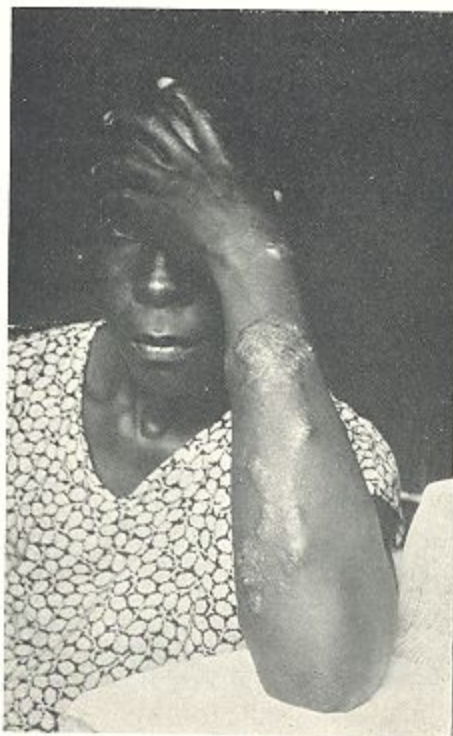

FIG. 14. CASE 13

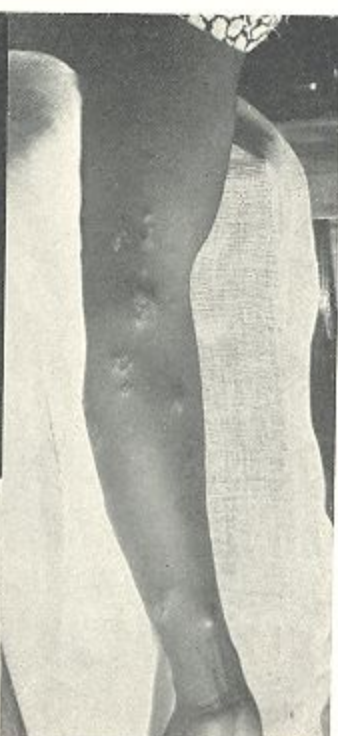


FIG. 15. CASE 13

believed that it is a massive and *accidental* infection by *T. pertenu*e of the lymphatic system of the forearm and arm. The negative darkfields may be accounted for if the organisms have only invaded the lymphatic system; specimens for darkfield examination were taken from tissue away from where the *T. pertenu*e should be found in this case—near the points of first attack within the lymphatics. Within two weeks after the first dose of 0.45 gram neosalvarsan the improvement was remarkable.

The deep chain of beadlike glands had completely resolved to palpation, and all those which were larger and nearer the surface were greatly reduced in size and there was some concentration of pigment of the skin over the site of reaction. Two subsequent doses of neosalvarsan resulted in complete disappearance of gross pathology.

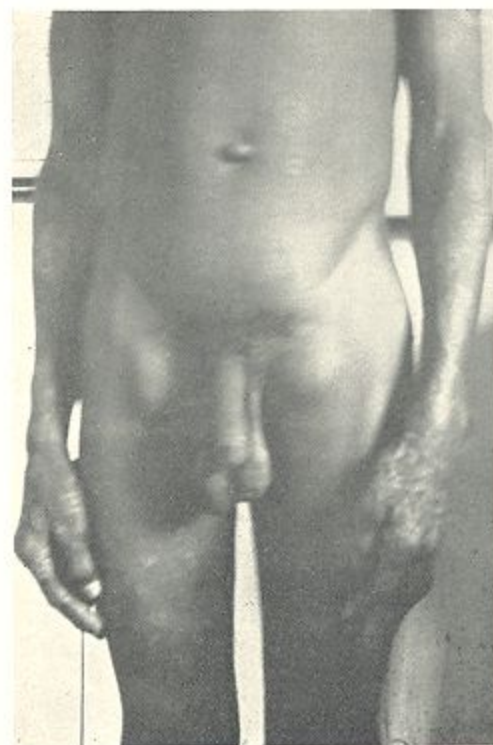

FIG. 16. CASE 14

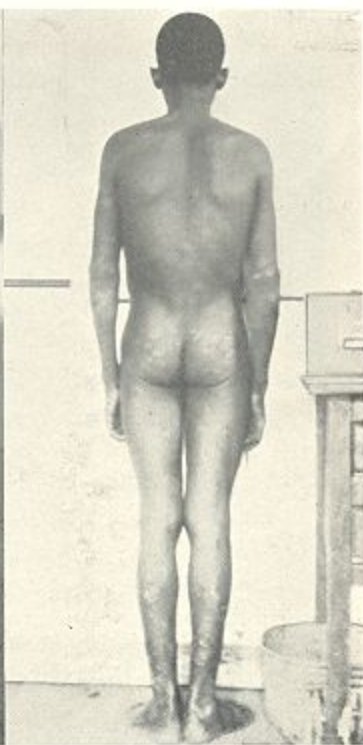


FIG. 17. CASE 14

Case 14. (Figs. 16, 17 and 18.) Boy of seventeen years, mother yaw first observed by the patient on the index finger of the left hand one year earlier. Four months later, without any of the usual secondary yaws lesions having appeared, the dry, circinate, ringworm-like rash came out over the entire body and has persisted up to the time of these pictures taken eight months later. The rash is more marked on the extremities. There were no open lesions and there was no oozing of serum. Furfuraceous scaling of most of the patches was a marked feature. The dactylitis-like involvement of the middle phalangeal joints of all the

fingers of the left hand was first noticed by the patient within a few days after the appearance of the skin lesions. Two months later he noticed that the middle metacarpo-phalangeal joint of the right hand became involved together with all the middle phalangeal joints of the right hand but to a less extent than that observed in the figures of the left. Patient complained of slight, constant pain in all the joints involved. The only adenopathy noted was in the inguinal glands. Both groups were enormously enlarged, of a doughy consistency, and they were not tender. They were first noticed by the patient a few days after the appearance of the skin lesions. Two weeks after the second injection of 0.45 gram neosalvarsan the skin lesions entirely disappeared, there was no more

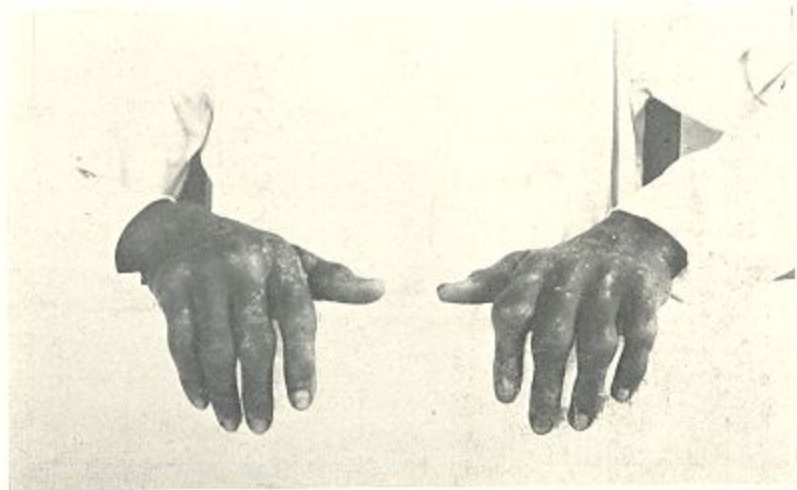


FIG. 18. CASE 14

pain, edema in the soft tissues around the affected joints entirely disappeared leaving the bones slightly enlarged, and the adenopathy of the inguinal glands was markedly reduced.

Case 15. (Fig. 19.) Man twenty years old—mother yaw ten years earlier over the internal malleolus of the right ankle. (Scar of the primary lesion may be seen in the plate.) Patient complained of slight, constant pain in the arms and legs and spindle-formed enlargements of both tibia, lower third of the right humerus and middle third of the left ulna were present. There was a general, slight adenopathy of the

inguinal, epitrochlear, axillary and cervical lymph glands. The onset of the bone involvement was first noticed by the patient about two years previous to the taking of the picture. Two injections of 0.45 gram neo-salvarsan relieved the patient from all pain. In this case the osteitis of only the right tibia appears to be a direct extension from a previous ulcer

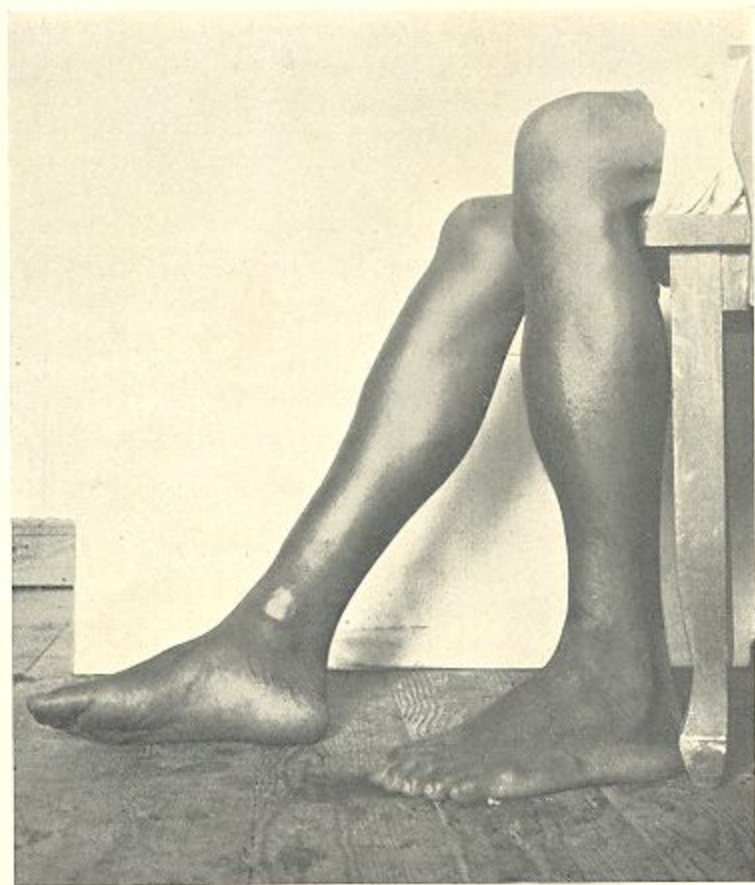


FIG. 19. CASE 15

on the site of the primary lesion. There were no open lesions or scars on the other extremities. Cases 14 and 15 were the only patients seen in the Panama series showing osteitis of bones with no evidence of direct extension through the overlying tissues from a yaws ulcer of the skin. Such cases are not unusual in Haiti.

Case 16. Columbian man, fifty-six years old, very light in color who had yaws twenty years earlier. Mother yaw was on the left ankle and only five secondary lesions "came out." These were all located on the left side of the abdomen. He has had a painful left knee for more than one year accompanied by some swelling around the joint. The inguinal glands alone show palpable adenopathy and those in the left groin are distinctly larger than those of the right side. Kahn and Wassermann tests negative on two occasions. The first injection of neosalvarsan apparently brought on a severe remission of malaria. Recovering from his malaria he noticed that his knee was considerably better. He was given Elixir of Iron, Quinine and Strychnine and potassium iodide for two months and there was further improvement. Following the second injection of neosalvarsan given three months after the first injection he had complete relief from pain and swelling in the knee. Of course there are many factors which argue against the arthritis being of yaws etiology, but the improvement following the second injection of neosalvarsan is strongly suggestive. Diagnosis based on therapy alone is never satisfactory but in Haiti the writer had seen so much "yaws rheumatism" or "douleur pain" as it is designated by the Haitiens that he felt justified in citing this case.

Table 1 showing the incidence of certain pathological findings in the Haitien as compared with the Panamanian series of cases is of interest. The group of cases under the heading "Limitation of late lesions to the same extremity where the primary lesion occurred" is mostly made up of those patients showing crab yaw (painful plantar keratosis) of one foot as a late manifestation of the infection with history and scar of the mother yaw on the same leg, usually below the knee.

Crab yaw is also the common late evidence of yaws infection in the group listed under "Limitation of late lesions to both legs or opposite leg from mother yaw." It is believed that "contact" between the two legs in a barefooted and barelegged population is the probable mechanism of this transfer of infection. In Panama, as in Haiti, the majority of primary sores occurred below the knee.

Under the heading "gangosa and saddle nose," both of the Panama cases were of the latter type. Both showed old scars of the face leading into the nares. The Haitien cases were di-

vided—6 cases of gangosa and 7 of saddle nose. All cases showed facial scars leading into the nose or in the direction of where the nose used to be. Parsons and Mathis (3) have stated that they have each seen one case of saddle nose in Haiti of probably yaws etiology without any scars on the face. The writer observed one

TABLE 1

Incidence of certain pathological findings in the Haitien as compared with the Panamanian series of cases

YAWS	PANAMA, 424 CASES		HAITI, 1423 CASES	
	Number of cases	Per cent	Number of cases	Per cent
Primary yaw persistent as an ulcer with history of passed secondaries	15	3.5	19	1.3
Primary yaw persistent as an ulcer without secondaries or other late lesion	20	4.7	40	2.8
Limitation of late lesions to the same extremity where the primary lesion occurred	69	16.2	119	8.3
<i>Total cases showing regional or local limitation of pathology</i>	<i>104</i>	<i>24.3</i>	<i>178</i>	<i>12.5</i>
Limitation of late lesions to both legs or opposite leg from mother yaw	77	14.3	No data	
Adenitis predominating in lymphatic glands draining the site of the primary lesion	61	15.3	No data	
Primary and secondary lesions limited to an area drained by a single group lymph glands	11	2.5	No data	
Re-infections	3	0.7	None	0.0
Gangosa and saddle nose	2	0.47	13	0.9
"Rheumatic pain"	18	4.2	667	46.8
Juxta articular nodes	19	4.4	6	0.42
Hemiplegia (cerebral hemorrhage or thrombosis) in patients under forty years of age	3	0.7	4	0.28
Aneurysm	1	0.23	2	0.14

early case in Guam who showed beginning destruction of the hard palate and septum, and without facial scars.

"Rheumatic pain" is an obscure heading, but the patients do obtain considerable relief in nearly all cases following arsenical therapy.

Juxta articular nodes are usually bilateral, but not always.

They are usually found in adults many years after all other evidences of yaws have disappeared. One case was seen in Panama in a child seven years old who had passed through her yaws infection one year before.

Attributing cerebral hemorrhage or cerebral thrombosis in young adults to yaws may be in error. It is believed that it is not due to syphilis in the cases listed. The Panama cases were 27, 32 and 38 years old, with histories of yaws at the ages of 5, 17 and 3 years and hemiplegia present since 7 years, 6 months and 2 months, respectively. History or other findings suggesting syphilis such as genital scars and history of abortions were negative in all cases of both the Panamanian and Haitien groups.

The same objection may be raised against listing aneurysm as of yaws etiology.

Case 17. The Panama case is a man sixty-five years old with a pulsating tumor in the suprasternal notch which he first noticed two years ago. Tracheal tug was elicited. He comes into the clinic for hoarseness, unproductive cough, pain in the chest and weakness since two weeks previous when he was called upon to make unusual exertion. He states that he has never had a venereal disease. There were no scars on the genitals. He has six healthy children. Wife has had no miscarriages. History of yaws when he was seven years old. The mother yaw was on the left leg, and he now shows a scar on the site of the primary sore.

This case would fall in the group such as the group of 8 cases cited by Choisser (4). The one great objection to naming yaws as the etiological factor in such cases is the practical impossibility of absolutely ruling out a syphilitic infection. In this connection three Haitien cases seen by the writer are cited as being of particular interest due to the fact that the aneurysms were diagnosed in early life.

Case 18. A Haitien boy of fifteen years was admitted to the Haitien General Hospital because of his cardiac symptoms. Radiographic examination revealed a large pulsating tumor blending into the supracardiac dullness in the mediastinum. The boy gave a history of yaws when a baby which his mother supported. Healed yaws scars were present on one leg. Also, on the ring finger of one hand he had a dacty-

litis which had been present several years. No genital scars. He left the hospital worse than when he entered, and he could not be observed longer.

Case 19. A girl of eighteen years was admitted to the same hospital complaining of cardiac pain, cough and weakness. X-ray (fluoroscopic and plate) revealed a widely dilated aortic arch. She obtained but little relief from her symptoms, insisted on returning home, and died three days later from a massive hemorrhage from the mouth. Autopsy could not be obtained. This girl gave a history of yaws infection when a little girl, exact age could not be remembered, but she said that it was among the earliest of her recollections. On the legs were a few scars that had the appearance of ulcer scars.

Case 20. A gendarme twenty-one years old, a patient in the same hospital, gave a history of yaws when a small boy (exact age could not be recalled). He also gave a history of a small "bouton" or boil on the shaft of the penis at the age of nineteen which discharged pus for one or two days and healed within a week without treatment. He died a short time after admission to the hospital and at autopsy he was found to have a large ruptured aneurysm of the abdominal aorta.

The blood Kahn was positive in all three of the above cases.

Without going into any discussion of the yaws-syphilis relationship, it is the opinion of the writer that yaws may rarely be the etiological factor in aneurysm, perhaps better expressed as "accidental" etiological factor. Certainly when the enormous incidence of yaws among the Haitien rural population is considered one would expect a much higher incidence of aneurysm than which has been found if *T. pertenuis* and *T. pallidum* are identical. This is further supported by the well established fact of the greater susceptibility of the negro race to cardio vascular pathology as a result of syphilis.

CONCLUSIONS AND SUMMARY

1. The yaws cases seen in Panama show a marked tendency to local and regional limitation of late pathology.
2. Compared with yaws in Haiti, this regional limitation in the Panama series is double that found among the Haitien cases.

3. The route of transmission of infection from the primary yaw to other parts of the skin surface can not be definitely traced in many instances but considerable evidence indicates an impetigo-like spread, i.e., a mechanical transfer of infectious material over the body surface.

4. Undoubtedly transfer of the infection within the body is accomplished through the lymphatic system or general circulation in a small percentage of cases.

5. With but two exceptions all periosteal cases in the Panama group were caused by direct extension of the infection from overlying ulcers.

6. The strain of *T. pertenue* found in Panama is a much less virulent strain than that encountered in Haiti.

7. "Dry yaws" eruption, either of the ringworm or non-progressive papular type, probably accounts for the long quiescent periods so frequently seen in cases of late yaws.

8. "Dry yaws" on the skin around joint protuberances probably indicates the portal of infection which later manifests itself as a juxta articular node.

9. It is believed that very rarely yaws may be the *accidental* etiological factor in aneurysm and cerebral thrombosis or cerebral hemorrhage of young adults.

I wish to express my appreciation to the officials of the Public Health Service of the Republic of Panama. It is they who have fitted out our clinic to a large extent and furnished us with medicines and supplies. I also wish to express my gratitude to Chief Pharmacist's Mate C. E. Martin, U. S. Navy, who has assisted in the clinic from the beginning and to Dr. L. B. Bates and the Board of Health Laboratory personnel, Ancon, for checking the Kahn results and doing the Wassermann test on all blood sera.

REFERENCES

- (1) WILSON AND MATHIS: Jour. Amer. Med. Assoc., April 26, 1930, xciv, 1289-1292.
- (2) SCHÖBL, OTTO: Philippine Jour. Sc., March, 1928, xxxv, 1209-1332.
- (3) PARSONS, R. P., AND MATHIS, M. S.: Personal communications.
- (4) CHOISSER, R. M.: U. S. Naval Med. Bul., July-October, 1929.